

# DUMPSBOSS.

**SEND - Endocrinology and Diabetes (Specialty Certificate Examination)**

**MRCPUK SEND**

**Version Demo**

**Total Demo Questions: 10**

**Total Premium Questions: 200**

**Buy Premium PDF**

**<https://dumpsboss.co>**

**[support@dumpsboss.co](mailto:support@dumpsboss.co)**

**support@dumpsboss.co**  
**dumpsboss.co**

## QUESTION NO: 1

An 18-year-old woman presented with a 2-month history of polyuria and polydipsia. She had been previously fit and well with regular periods. She was not taking any contraception.

Investigations:

serum potassium 5.2 mmol/L (3.5–4.9)

serum corrected calcium 2.30 mmol/L (2.20–2.60)

serum cortisol (09.00 h) 350 nmol/L (200–700)

She went on to have a water deprivation test, the results of which are detailed below.

time (h) serum osmolality (mosmol/kg) urine osmolality (mosmol/kg)

normal: 278–300 normal: 100–1000

08.30 289 52

11.30 292 82

14.30 301 153

15.30 - 172

She was then given intramuscular DDAVP® 2 micrograms at 16.00 h.

time (h) serum osmolality (mosmol/kg) urine osmolality (mosmol/kg)

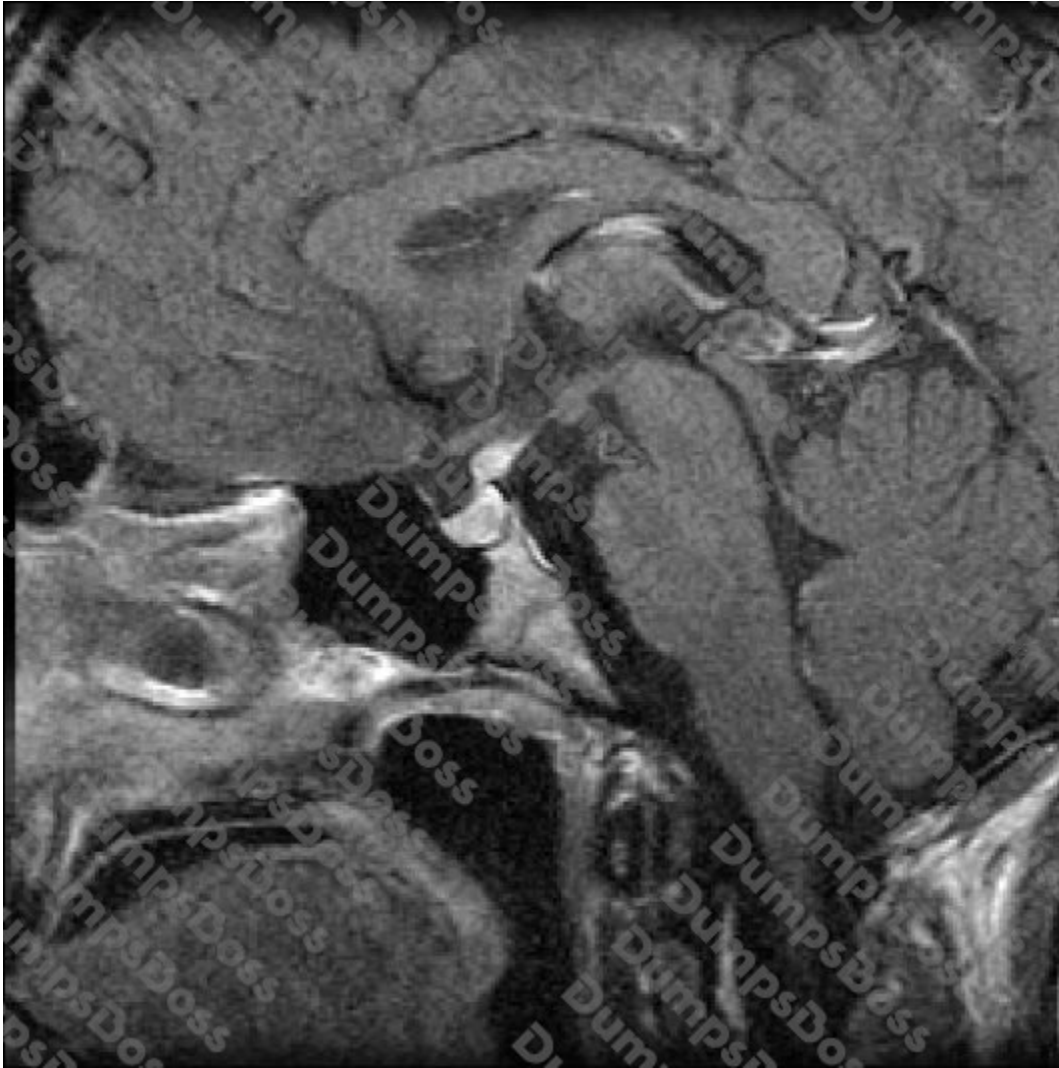
normal: 278–300 normal: 100–1000

16.30 300 -

17.30 - 530

18.30 - 532

Results from an MR scan of pituitary are shown (see image).



What is the most likely diagnosis?

- A. autoimmune (lymphocytic) hypophysitis
- B. craniopharyngioma
- C. non-functioning pituitary adenoma
- D. psychogenic polydipsia
- E. Rathke's cleft cyst

**ANSWER: A**

**QUESTION NO: 2**

A 61-year-old woman was found incidentally to have a raised serum calcium concentration. She was otherwise well. Her father had undergone a neck operation many years previously.

Investigations:

serum corrected calcium 2.78 mmol/L (2.20–2.60)

plasma parathyroid hormone 10.8 pmol/L (0.9–5.4)

Her general practitioner thought she had primary hyperparathyroidism.

Which further finding is most likely to cast doubt upon this diagnosis?

- A. high serum 25-OH-cholecalciferol
- B. low serum magnesium concentration
- C. low urinary calcium excretion
- D. normal parathyroid radioisotope scan (sestamibi scan)
- E. normal serum phosphate concentration

**ANSWER: C**

## QUESTION NO: 3

A 56-year-old woman presented with a swelling in her neck, which she had noticed by chance 6 weeks previously. The swelling had not changed in size since she first noticed it, and was completely asymptomatic.

On examination, there was a smooth nodule in the thyroid that moved up on swallowing and there was no lymphadenopathy.

Investigations:

ultrasound scan of thyroid single 4.7-cm hypoechoic nodule

in upper left lobe

serum thyroid-stimulating hormone 0.8 mU/L (0.4–5.0)

What is the most appropriate next step in management?

- A. FDG-PET CT scan
- B. fine-needle aspiration for cytology
- C. hemithyroidectomy
- D. isotope uptake scan
- E. serial ultrasound examinations

**ANSWER: B**

## QUESTION NO: 4

A 36-year-old man of African origin attended the clinic 2 weeks after discharge from hospital following his first admission with diabetic ketoacidosis. He had made a rapid recovery and had been discharged taking subcutaneous insulin twice daily.

At clinic, he reported home blood glucose measurements of 4–6 mmol/L, occasional symptomatic hypoglycaemia and a total daily insulin dose of 12 units. He asked if his glucose-lowering treatment should change.

Which test is most likely to predict prolonged insulin independence?

- A. anti-glutamic acid decarboxylase antibodies
- B. anti-islet cell antibodies
- C. fasting C-peptide concentration
- D. genotyping for monogenic diabetes
- E. glucagon-stimulated C-peptide concentration

**ANSWER: E**

## QUESTION NO: 5

A 64-year-old woman presented with features of acromegaly. An MR scan showed a pituitary tumour with cavernous sinus extension. She underwent trans-sphenoidal surgery and histology of the pituitary tissue showed numerous cells immunostaining for growth hormone.

Investigations (6 months postoperatively):

MR scan of pituitary enlarged sella, residual tumour in right cavernous sinus

serum growth hormone (day curve average) 3.2 µg/L (<2)

serum insulin-like growth factor 1 42.0 nmol/L (3.3–23.3)

What is the most appropriate next step in management?

- A. conventional external beam radiotherapy to pituitary region
- B. long-acting octreotide
- C. pegvisomant
- D. repeat trans-sphenoidal surgery
- E. watchful waiting

**ANSWER: B**

## QUESTION NO: 6

A 55-year-old male-to-female transsexual was reviewed in clinic. She lived as a woman but had not undergone gender reassignment surgery. She was treated with cyproterone acetate 50 mg twice daily and estradiol 2 mg twice daily.

What are the most important tests for monitoring safe replacement?

- A. lipid profile and liver function tests
- B. lipid profile and serum prostate-specific antigen
- C. liver function tests and full blood count
- D. liver function tests and serum prostate-specific antigen
- E. serum prostate-specific antigen and full blood count

**ANSWER: A**

## QUESTION NO: 7

A 36-year-old woman was seen in the clinic with a recurrence of hyperthyroidism after a 2-year remission. She had been treated with carbimazole for 18 months following her original presentation. She was moderately symptomatic and was keen to be treated in the same way again. She was planning a pregnancy.

Investigations:

serum prolactin 240 mU/L (<360)

serum thyroid-stimulating hormone <0.1 mU/L (0.4–5.0)

serum free T4 28.0 pmol/L (10.0–22.0)

anti-thyroid-stimulating hormone receptor

antibodies 44 U/L (<7)

What is the most appropriate next step in management?

- A. block-and-replace treatment with carbimazole and levothyroxine
- B. carbimazole
- C. propylthiouracil
- D. radioiodine treatment
- E. referral for thyroidectomy

**ANSWER: C**

## QUESTION NO: 8

A 26-year-old woman presented acutely with abdominal pain.

On examination, her blood pressure was 124/72 mmHg.

Investigations:

24-h urinary dopamine 10 000 nmol (<3100)

24-h urinary adrenaline 43 nmol (<144)

24-h urinary noradrenaline 146 nmol (<570)

CT scan of abdomen 3-cm left para-aortic mass

She underwent surgical exploration and removal of the lesion, which proved to be a paraganglioma. One local lymph node, removed at the same time, was also positive for the presence of tumour.

What is the most likely underlying genetic syndrome?

- A. Gardner's syndrome
- B. multiple endocrine neoplasia type 2a
- C. neurofibromatosis type 1 mutation
- D. succinate dehydrogenase type B mutation
- E. von Hippel–Lindau syndrome

**ANSWER: D**

## QUESTION NO: 9

A 73-year-old man with type 2 diabetes mellitus was reviewed because of borderline hypertension. He was taking metformin 1 g twice daily, gliclazide 160 mg twice daily, aspirin 75 mg daily and simvastatin 20 mg at night. He had a history of diabetic retinopathy.

On examination, his body mass index was 34 kg/m<sup>2</sup> (18–25); his blood pressure was 146/86 mmHg. When he returned 2 months later, his blood pressure was 142/88 mmHg.

Investigations:

serum creatinine 102 µmol/L (60–110)

haemoglobin A1c 66 mmol/mol (20–42)

urinary albumin:creatinine ratio

(untimed specimen) 7.4 mg/mmol (<2.5)

According to NICE guidelines (CG66, May 2008), what is the target for blood pressure reduction?

- A. <120/70 mmHg
- B. <125/70 mmHg
- C. <130/80 mmHg
- D. <140/80 mmHg
- E. <150/90 mmHg

**ANSWER: C**

## QUESTION NO: 10

An 18-year-old man presented with delayed puberty.

On examination, he had a high arched palate. His sense of smell was intact, and he had a family history of pubertal delay. Kallman's syndrome was suspected.

Investigations:

serum testosterone 0.3 nmol/L (9.0–35.0)

serum follicle-stimulating hormone 1.0 U/L (1.0–7.0)

serum luteinising hormone 1.0 U/L (1.0–10.0)

bone age 15 years

What further clinical finding would most strongly support the diagnosis of Kallman's syndrome?

- A. bimanual synkinesia (mirror movements)
- B. eunuchoid habitus
- C. night blindness
- D. short stature
- E. testes 6 mL bilaterally

**ANSWER: A**