

DUMPSBOSS.

Advanced Cardiac Life Support

Test Prep ACLS

Version Demo

Total Demo Questions: 15

Total Premium Questions: 354

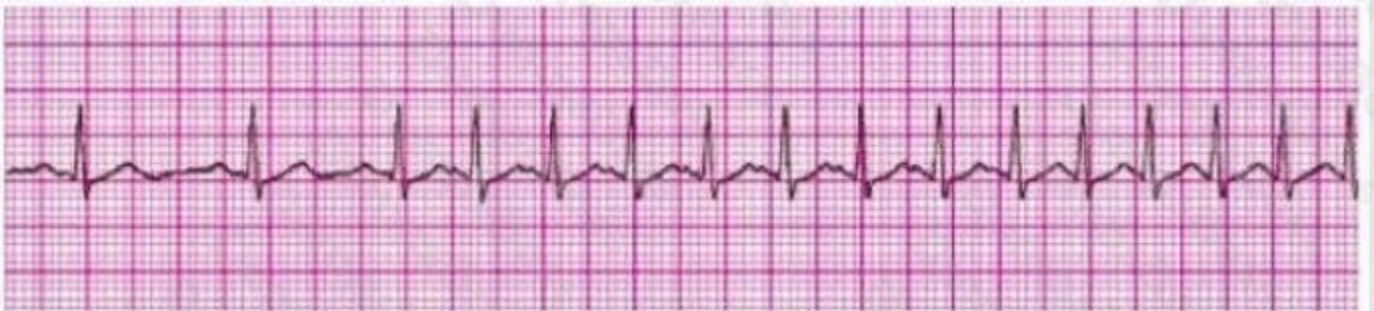Buy Premium PDF

<https://dumpsboss.co>

support@dumpsboss.co

support@dumpsboss.co
dumpsboss.co

QUESTION NO: 1

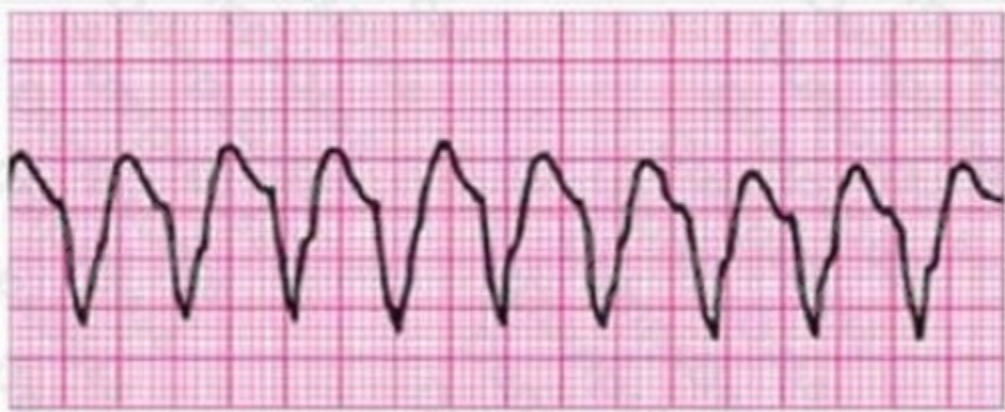

Identify the rhythm by selecting the best single answer:

- A. Normal sinus rhythm
- B. Sinus tachycardia
- C. Sinus bradycardia
- D. Reentry supraventricular tachycardia
- E. First-degree AV Block
- F. Second-degree AV Block (Mobitz 1 Wenckebach)
- G. Second-degree AV Block (Mobitz II Block)
- H. Third-degree AV Block
- I. Atrial fibrillation
- J. Atrial flutter
- K. Monomorphic ventricular tachycardia
- L. Polymorphic ventricular tachycardia
- M. Coarse ventricular fibrillation
- N. Fine ventricular fibrillation
- O. Agonal rhythm/asystole
- P. Pulseless electrical activity

ANSWER: D

QUESTION NO: 2



You are monitoring a patient. Chest discomfort has been relieved with sublingual nitrates and morphine sulfate 4 mg IV. He suddenly has the above persistent rhythm. You ask about symptoms and he reports mild palpitations, but otherwise he is clinically stable with unchanged vital signs. Your next action is:

- A. Give sedation and perform synchronized cardioversion
- B. Administer amiodarone 150 mg over 10 minutes; seek expert consultation
- C. Give immediate synchronized shock
- D. Give immediate unsynchronized shock
- E. Administer magnesium sulfate 1 to 2 g IV diluted in 10 mL D5W given over 5 to 20 minutes

ANSWER: B

QUESTION NO: 3

Dopamine infused at greater than 10 mcg/kg/min will cause:

- A. increased myocardial contractility
- B. peripheral arterial vasoconstriction
- C. renal artery vasoconstriction
- D. respiratory depression

ANSWER: A B C

QUESTION NO: 4

In rescuing a near drowning victim, the rescuer should:

- A. compress the chest to drain water from breathing passages.

- B. assure their own safety.
- C. stabilize the cervical spine if a diving accident.
- D. start rescue breathing.

ANSWER: B C D

QUESTION NO: 5 - (FILL BLANK)

ORRECT TEXT

A patient with pulseless electrical activity is undergoing CPR. Exam reveals distended neck veins. What diagnosis should be considered and how should it be ruled out?

ANSWER: Cardiac tamponade should be ruled out by performing pericardiocentesis.

Explanation:

QUESTION NO: 6

Ventricular fibrillation:

- A. may be mimicked by artifact on the monitor
- B. may produce a peripheral pulse
- C. produces no cardiac output
- D. treated with early defibrillation

ANSWER: A C D

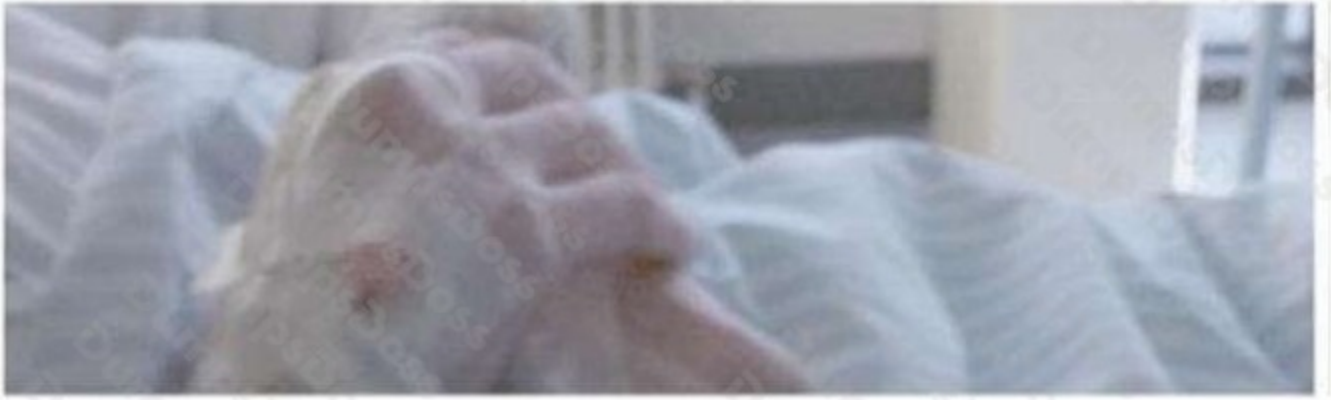QUESTION NO: 7 - (FILL BLANK)

ORRECT TEXT T/F: Beta-blockers depress the pumping function of heart muscle.

ANSWER: True

Explanation:

QUESTION NO: 8

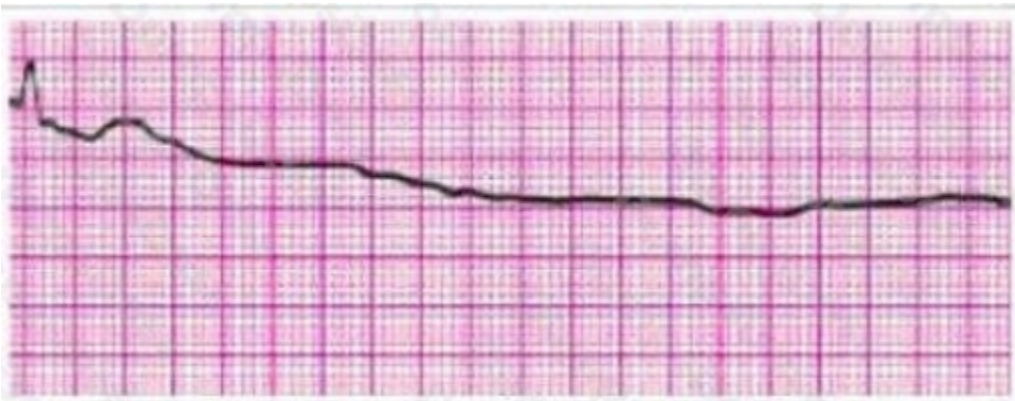


A patient with a possible ST-segment elevation MI has ongoing chest discomfort. Which of the following would be a contraindication to the administration of nitrates?

- A. Use of phosphodiesterase inhibitor within 12 hours
- B. Left ventricular infarct with bilateral rates
- C. Blood pressure greater than 180 mmHg
- D. Heart rate 90 per minute

ANSWER: B

QUESTION NO: 9



Identify the rhythm by selecting the best single answer:

- A. Normal sinus rhythm
- B. Sinus tachycardia
- C. Sinus bradycardia
- D. Reentry supraventricular tachycardia

- E. First-degree AV Block
- F. Second-degree AV Block (Mobitz 1 Wenckebach)
- G. Second-degree AV Block (Mobitz II Block)
- H. Third-degree AV Block
- I. Atrial fibrillation
- J. Atrial flutter
- K. Monomorphic ventricular tachycardia
- L. Polymorphic ventricular tachycardia
- M. Coarse ventricular fibrillation
- N. Fine ventricular fibrillation
- O. Agonal rhythm/asystole
- P. Pulseless electrical activity

ANSWER: O

QUESTION NO: 10 - (FILL BLANK)

How does the pharynx in an adult and child differ?

ANSWER: Infant and children's tongues take up proportionally more space in the mouth than adults do.

Explanation:

QUESTION NO: 11

Regarding epinephrine, which of the following statements are true?

- A. increases coronary perfusion
- B. IV bolus dose is 1 mg q 3-5 minutes
- C. treatment for hypotensive ventricular tachycardia
- D. increases cerebral blood flow during CPR

ANSWER: A B C

QUESTION NO: 12

An incubated patient develops sudden onset narrow complex tachycardia, at a rate of 130 beats per minute.

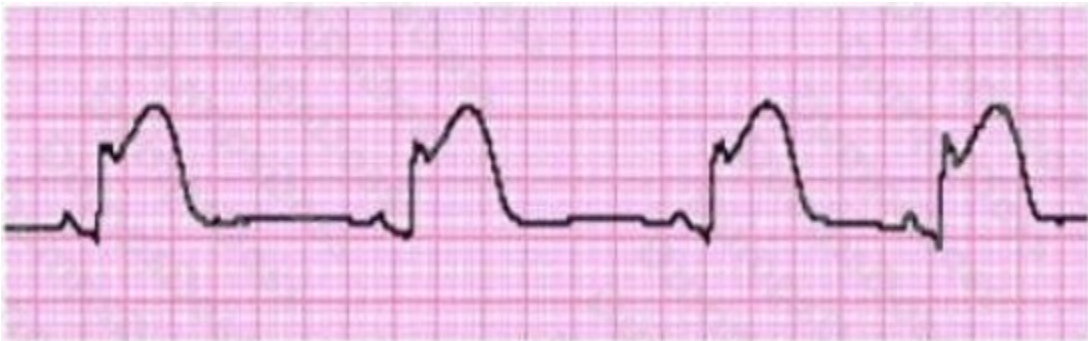Vital signs are 0-0-0. CPR is in progress. The most important action is:

- A. find the cause of the arrest
- B. give 1 mg epinephrine IVP
- C. give verapamil 5 mg IVP
- D. cardiovert at 360 J

ANSWER: B**QUESTION NO: 13**

What are the end points of a procainamide loading infusion in the non-arrest situation?

- A. pretreatment QRS complex is widened by 50%
- B. hypotension
- C. 17 mg/kg drug has been injected
- D. the dysrhythmia is suppressed
- E. All of the above

ANSWER: E**QUESTION NO: 14**

Identify the rhythm by selecting the best single answer:

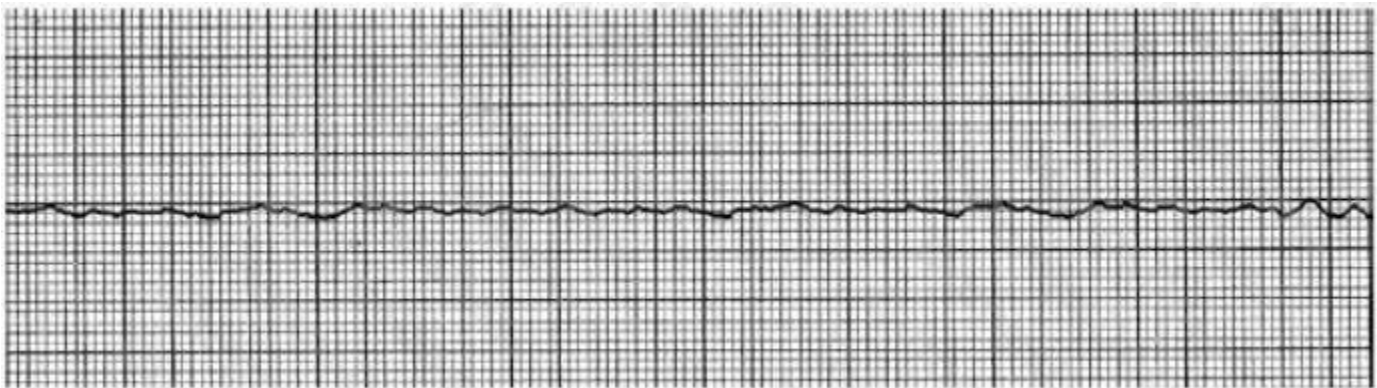- A. Normal sinus rhythm

- B. Sinus tachycardia
- C. Sinus bradycardia
- D. Reentry supraventricular tachycardia
- E. First-degree AV Block
- F. Second-degree AV Block (Mobitz 1 Wenckebach)
- G. Second-degree AV Block (Mobitz II Block)
- H. Third-degree AV Block
- I. Atrial fibrillation
- J. Atrial flutter
- K. Monomorphic ventricular tachycardia
- L. Polymorphic ventricular tachycardia
- M. Coarse ventricular fibrillation
- N. Fine ventricular fibrillation
- O. Agonal rhythm/asystole
- P. Pulseless electrical activity

ANSWER: C

QUESTION NO: 15

You are performing synchronized cardioversion when the following rhythm suddenly appears. What is the recommended immediate treatment?



- A. lidocaine 100 mg IV bolus
- B. begin CPR

- C. unsynchronized countershock at 200 J
- D. synchronized shock at 200 J

ANSWER: C