

# DUMPSBOSS.

## United States Medical Licensing Examination

Test Prep USMLE

Version Demo

Total Demo Questions: 20

Total Premium Questions: 622

Buy Premium PDF

<https://dumpsboss.co>

[support@dumpsboss.co](mailto:support@dumpsboss.co)

support@dumpsboss.co  
dumpsboss.co

## QUESTION NO: 1

A 59-year-old man is brought to the emergency department because of a 4-day history of nausea, vomiting, and diarrhea. He also has been confused and agitated during this period. He has a history of mild hypertension. His current medication is a diuretic. His temperature is 37°C (98.6°F), pulse is 108/min, respirations are 26/min, and blood pressure is 70/47 mmHg. Physical examination shows delayed capillary refill of the lips and nail beds and cool extremities. His oxyhemoglobin saturation in a central vein is 60% (N = 70 - 75). These findings are most consistent with which of the following types of shock?

- A. Cardiogenic
- B. Distributive
- C. Hypovolemic
- D. Obstructive
- E. Septic

**ANSWER: C**

## QUESTION NO: 2

Which of the following is not a risk factor for hypertension?

- A. Genetics
- B. Obesity
- C. Youth
- D. Smoking

**ANSWER: C**

## QUESTION NO: 3

A previously healthy 24-year-old woman who is a college student comes to the office because of a 6-month history of abdominal bloating, upper abdominal discomfort, and constipation. The symptoms are more severe when she is preparing for examinations but improve after bowel movements. She takes no medications. She does not smoke or use illicit drugs. She drinks alcoholic beverages occasionally. She is 160 cm (5 ft 3 in) tall and weighs 57 kg (125 lb); BMI is 22 kg/m<sup>2</sup>. Her pulse is 72/min, and blood pressure is 100/72 mmHg. Physical examination, including digital rectal examination, shows no other abnormalities. A complete blood count and serum electrolyte concentrations are within the reference ranges. A urease breath test result is negative. Upper and lower endoscopies show no abnormalities. Which of the following is the most appropriate pharmacotherapy for this patient?

- A. Azathioprine

- B. Infliximab
- C. Lubiprostone
- D. Mesalamine
- E. Sulfasalazine

**ANSWER: C**

## QUESTION NO: 4

Chagas' disease is commonly treated with Nifurtimox and is linked to the \_\_\_\_ microorganism.

- A. Naegleria
- B. Schistosoma
- C. Wuchereria bancrofti
- D. Trypanosoma cruzi

**ANSWER: D**

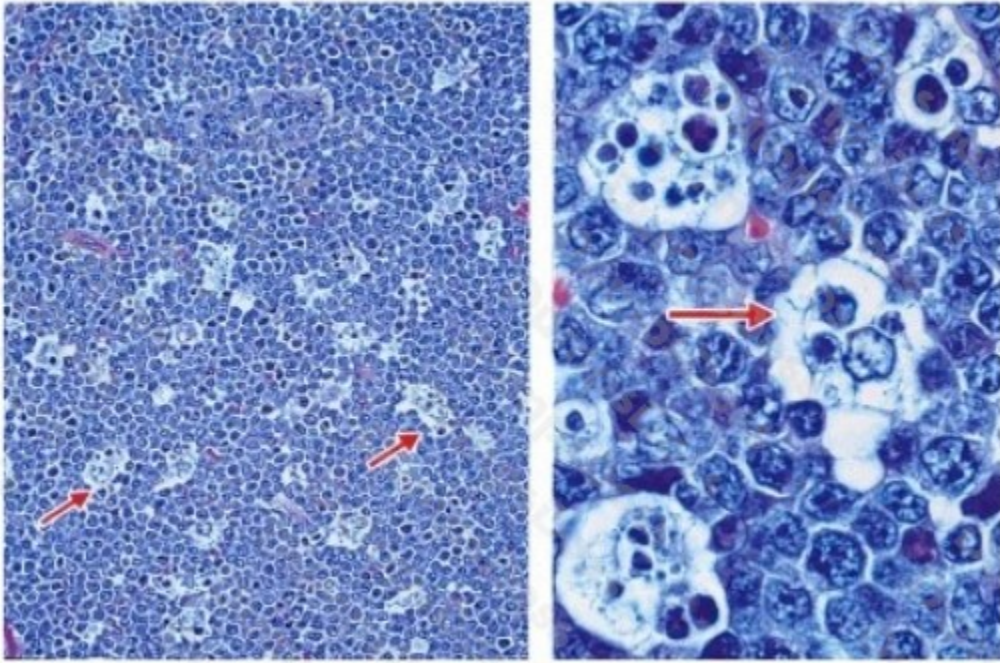
## QUESTION NO: 5

Supporting cells located within the CNS are collectively called \_\_\_\_\_.

- A. Neuroglia
- B. Astrocytes
- C. Perikaryon
- D. Satellite cells

**ANSWER: A**

## QUESTION NO: 6



A 4-year-old boy from Brazil is brought to the physician because of a 1-week history of painless swelling of his jaw and pressure around his eyes. He is at the 80th percentile for height and weight. Physical examination shows a single 12 × 10-cm lesion in the right side of the jaw with diffuse limits and irregular edges. Photomicrographs of an incisional biopsy specimen of the lesion are shown. Based on these findings, which of the following processes is most likely occurring in the region indicated by the arrows?

- A. Apoptosis
- B. Necrosis
- C. Oncosis
- D. Ostosis
- E. Symptosis

**ANSWER: A**

#### QUESTION NO: 7

A 65 year-old man is admitted to the coronary care unit with a diagnosis of a large myocardial infarct (MI) of the left ventricle. On his 6th postinfarct day, he goes into shock and dies, manifesting signs and symptoms of cardiac tamponade. Which of the following complications is the most likely cause of this patient's death?

- A. Aortic dissection
- B. Extension of previous MI
- C. Fatal arrhythmia

- D. Rupture of the left ventricular wall
- E. Rupture of papillary muscle

**ANSWER: D**

**Explanation:**

Rupture of the free left ventricular wall is a frequently fatal complication that may occur in the first week after myocardial infarction (MI). At this stage, the infarcted area is composed of friable necrotic myocardium and early granulation tissue. It is during this crucial phase, therefore, that rupture usually occurs. Blood rushes out, filling the pericardial sac and causing compression of the left ventricle. Cardiac tamponade ensues, and the patient usually dies of acute cardiogenic shock. Aortic dissection is not a complication of MI, although cardiac tamponade may also follow this acute condition when dissection works its way back toward the aortic root. Aortic dissection usually develops in aortas affected by cystic medial degeneration (CMD), which is due to fragmentation of elastic laminae with accumulation of myxoid material in the aortic media. CMD may be either sporadic or associated with Marfan syndrome. Extension of a previous MI may occur in the first few hours or days after MI. It may aggravate or precipitate cardiogenic shock and/or arrhythmias, but it does not cause cardiac tamponade. Arrhythmias are frequent complications of MI and are often fatal, producing cardiac arrest (ventricular fibrillation) or aggravating cardiac dysfunction. If infarction involves papillary muscles, these may rupture. This complication is followed by valvular dysfunction and may manifest with signs of mitral regurgitation and acute congestive heart failure.

**QUESTION NO: 8**

A 14-year-old girl is brought to the physician after her mother learned that she began having sexual intercourse with various partners 1 month ago. She does not use condoms or other contraception. The mother is concerned about her behavior. The patient's parents separated 3 months ago. She had been an honor student and excelled in sports and leadership positions at school before the separation. Since the separation, however, she has become sullen, defiant, and rebellious. She has begun smoking cigarettes, disobeying her curfew, and being truant from school. This patient is most likely using which of the following defense mechanisms?

- A. Acting out
- B. Displacement
- C. Projection
- D. Reaction formation
- E. Sublimation

**ANSWER: A**

**QUESTION NO: 9**

If you are using a stethoscope and trying to detect the tricuspid valve which of the following would be the best location?

- A. Within 2 inches of the xiphoid process
- B. On the right side of the sternum

- C. On the left side of the sternum near the midpoint
- D. On the left side of the sternum near the midpoint of the sixth rib

**ANSWER: A**

## QUESTION NO: 10

A 72-year-old woman comes to the physician because of a 3-day history of fever, shortness of breath, difficulty swallowing, chest pain, and cough. She is frail. Physical examination shows tachypnea and equal pulses bilaterally. Percussion of the chest shows dullness over the right lower lung field. Laboratory studies show arterial hypoxemia and decreased PCO<sub>2</sub>. A chest x-ray shows an area of opacification in the lower region of the right lung. Which of the following is the most likely cause of this patient's condition?

- A. Alveolar proteinosis
- B. Aspiration
- C. Cigarette smoking
- D. Emphysema
- E. Vasculitis

**ANSWER: B**

## QUESTION NO: 11

Which of the following is an effect of a diuretic?

- A. Decreased Cardiac Output
- B. Increased fluid volume
- C. Increased sodium re-absorption
- D. Increased chloride ion re-absorption

**ANSWER: A**

## QUESTION NO: 12

Vitamin D is created from \_\_\_\_\_ by skin cells.

- A. Dehydrocholesterol
- B. Cholesterol

- C. Hydrocholesterol
- D. Hydrodermis

**ANSWER: A**

## QUESTION NO: 13

Down syndrome is directly linked to a genetic abnormality of chromosome?

- A. XXII
- B. XXI
- C. XIIX
- D. XV

**ANSWER: B**

## QUESTION NO: 14

A 14-year-old girl has had nausea, intermittent diarrhea, and a 2.2-kg (5-lb) weight loss over the past 4 weeks. Examination shows a migrating serpiginous pruritic perianal rash. Her leukocyte count is 8000/mm<sup>3</sup> with 20% eosinophils. Which of the following tests is most likely to yield an accurate diagnosis?

- A. Blood smear
- B. Bone marrow biopsy
- C. KOH preparation
- D. Microscopic examination of the stool
- E. Skin snip

**ANSWER: D**

## QUESTION NO: 15

A 19-year-old female is brought to the emergency department after she collapsed while jogging. She has a history of anorexia nervosa. When she regains consciousness, she says as she was jogging she became lightheaded, broke out into a sweat, and had palpitations. Her fingerstick glucose is 40 mg/dL. Her palpitations and diaphoresis were most likely caused by

- A. ACTH

- B. calcitonin
- C. epinephrine
- D. insulin
- E. thyroxine

**ANSWER: C**

**Explanation:**

Exercising in patients with anorexia nervosa can trigger or worsen the effects of hypoglycemia. This occurs because lipid stores are not available to meet the current energy needs. The body responds to the hypoglycemia with an epinephrine burst from the adrenal medulla. The lack of available glucose and ATP for the brain causes dizziness or lightheadedness. Sympathetic activation by epinephrine leads to the induction of gluconeogenesis, stimulation of cardiac beta-1 receptors and stimulation of skin receptors.

**QUESTION NO: 16**

A 12-year-old girl is brought to the physician because of a 2-month history of intermittent yellowing of the eyes and skin. Physical examination shows no abnormalities except for jaundice. Her serum total bilirubin concentration is 3 mg/dL, with a direct component of 1 mg/dL. Serum studies show a haptoglobin concentration and AST and ALT activities that are within the reference ranges. There is no evidence of injury or exposure to toxins. Which of the following additional findings is most likely in this patient?

- A. Decreased activity of UDP glucuronosyltransferase
- B. Gallstones
- C. Increased hemolysis
- D. Increased serum alkaline phosphatase activity
- E. Ineffective erythropoiesis

**ANSWER: A**

**QUESTION NO: 17**

A 24-year-old AIDS patient develops chronic abdominal pain, low-grade fever, diarrhea, and malabsorption. Oocysts are demonstrated in the stool. Which of the following organisms is most likely to be the cause of the patient's diarrhea?

- A. Diphyllbothrium latum
- B. Entamoeba histolytica
- C. Giardia lamblia
- D. Isospora belli

## E. Microsporidia

**ANSWER: D**

### Explanation:

All the organisms listed are protozoa. There are two intestinal protozoa specifically associated with AIDS that can cause transient diarrhea in immunocompetent individuals but can cause debilitating, and potentially life-threatening, chronic diarrhea in AIDS patients. These organisms are *Isospora belli*, treated with trimethoprim sulfamethoxazole or other folate antagonists) and *Cryptosporidium parvum* (no treatment currently available). *Diphyllobothrium latum* is the fish tapeworm and occasionally causes diarrhea. *Entamoeba histolytica* and *Giardia lamblia* are both causes of diarrhea, but they are not specifically associated with AIDS. Microsporidia are a protozoan cause of diarrhea but produce spores rather than oocysts.

### QUESTION NO: 18

A previously healthy 40-year-old man is brought to the emergency department because of constant substernal chest pain for 12 hours that is exacerbated by coughing and inspiration. The pain is relieved with sitting up and leaning forward. There is no family history of heart disease. His temperature is 38°C (100.4°F), pulse is 120/min, and blood pressure is 110/60 mmHg. The lungs are clear to auscultation. Cardiac examination shows distant heart sounds. An ECG shows diffuse ST-segment elevation in all leads. An x-ray of the chest shows normal findings. The most likely cause of his condition is injury to which of the following tissues?

- A. Aortic intima
- B. Esophageal sphincter
- C. Myocardium
- D. Pericardium
- E. Pleura

**ANSWER: D**

### QUESTION NO: 19

What type of cells secretes insulin?

- A. Beta cells
- B. Alpha cells
- C. Plasma cells
- D. Acinar cells

**ANSWER: A**

## QUESTION NO: 20

Which of the following is not directly related with pheochromocytoma?

- A. Pallor
- B. Perspiration
- C. Decreased blood pressure
- D. Headaches

**ANSWER: C**